

Comparison of effect of botulinum toxin with clopidogrel and concomitant prescription of them in the survival of random skin flap in rats

Ferdos Moznebi, MD¹ Ghasemali KHorasani, MD² Seyed Abouzar Hoseini, MD³ Kourosh GHanbarzadeh, MD⁴
Massoud Amanlou, MD⁵ Batool Ghorbani Yekta, MD⁶

Assistant Professor Department of Surgery¹, Hormozgan University of Medical Sciences, Bandar Abbas, Iran. Associate Professor Department of Surgery², Tehran University of Medical Sciences, Tehran, Iran. Pathologist³, Iran University of Medical Sciences, Tehran, Iran. Assistant Professor Department of Surgery⁴, Tehran University of Medical Sciences, Tehran, Iran. Professor Department of Pharmacy⁵, Tehran University of Medical Sciences, Tehran, Iran. Associate Professor Department of Internal Medicine⁶, Neuroscience Research Center, Azad University, Tehran Branch, Tehran, Iran.

(Received 6 Aug, 2014 Accepted 16 Sep, 2014)

ABSTRACT

Introduction: In this study, the effect of botulinum toxin A and clopidogrel and concomitant administration of them in the survival of random skin flap in rat model were studied.

Methods: First in all rats, flaps of 3×10 cm was created, the first group was the control group, in the second group immediately after surgery, botulinum toxin with dose of (international unit) 1.5 IU for was injected as intradermal. In the third group, immediately after surgery, clopidogrel powder that was previously dissolved in the solution of sodium chloride, orally using OGT (Orogastric Tube) and with a dose of 25 mg/Kg was fed to animal. In the fourth group, after surgery, botulinum toxin like the second group and Plavix combination like the third group with the same dose was prescribed. After 7 days, level and flap cutting was measured and calculated by morphology and pathology.

Results: The mean of necrosis in control group was 21±2, in botulinum toxin A was 9.3±0.8, in clopidogrel group was 14±1.7 and in clopidogrel+botulinum toxin A was 12.6±1.5 percent. The difference was statistically significant between groups (P<0.0001).

Conclusion: The finding of our study showed that injection of botulinum toxin A compared to control group and compared to clopidogrel group and combination of clopidogrel with botulinum toxin A show greater effect in the survival of flap and reducing distal necrosis.

Correspondence:
Ghasemali. Khorasani, MD.
Surgery Department, Imam
Khomeini Hospital Complex,
Tehran University of Medical
Sciences.
Tehran, Iran
Tel: +98 912 7213948
Email:
GAKhorasani@yahoo.com

Key words: Flap, Necrosis, Botulinum Toxins, Clopidogrel

Introduction:

Random skin flap is one of the most common surgery in plastic and reconstructive surgery. The coordination of these flaps in terms of color and consistency and thickness with initial tissue compared with other methods of restorative has increased the importance of these flaps. Flap

necrosis is still considered as one of the very important complications in the reconstructive surgeries. For ease of using various flaps and increase their use, different modifications and refinements can be applied. Skin random flaps have different limitations, such as limitations of length to width ratio, limitation of the amount of rotation (Arc of rotation), proximity of flap to the wound or

deficiency and placing flap in Zone of injury. Unfortunately flap distal necrosis is one of the occurrences that cannot always be prevented by proper design of the flap (1). Several medications such as topical medications have been investigated in preventing ischemic flap, including sympatholytics, vasodilators, calcium channel blockers, inhibitors of prostaglandin, anticoagulant, and glucocorticoids and free radical absorbers that recommended in survival of flap can be useful, most of these drugs cause vasodilatation and increase blood flow of flap (2). The main disadvantage of these drugs is this that often is effective when used in high doses systemically and so will follow many systematic side effects that of course, in the case of topical use, these effects will be less (3). The pathogenesis of ischemia are not well known, but several mechanisms such as vasospasm, blood flow in arterial-venous shunt, vascular endothelial cell injury, intravascular thrombosis of microcirculation, tissue damage due to ischemia for it to be considered. Initial ischemia due to pick up flap enough in creating necrosis is significant, most previous studies have shown that most of tissues can survive by 10% average blood flow (4). Necrosis in flap causes significant morbidity, more surgery and longer stay of patient in the hospital. Various methods are used for increasing the survival of the flap using different drugs. In recent years, the use of antiplatelet medications as a new approach is considered in increasing flap survival. Previous studies on drugs of enoxaparin, aspirin and Plavix (clopidogrel bisulfate) represent the relatively good effects of these drugs on flap survival (5-7). Plavix (clopidogrel bisulfate) is derived of Ticlopidin that irreversibly and by binding to adenylyl cyclase receptors coupled to adenosine diphosphate prevents platelet aggregation. In animal studies has been shown that Plavix lead to the reduction of venous and arterial thrombosis (6).

Few studies have done to evaluate the effect of botulinum toxin on skin flap survival (8-10). In the study of Kim and colleagues, Botox injections showed the increase of 8.3% in the skin flaps. Histologic investigation of above samples showed that the diameter of the vessels and the number of immature blood vessels in the samples under treated with Botox has increased. PCR study of above

samples indicates the increase of incidence of Vascular Thrombosis Factor, CD31 and inducible Nitric Oxidase Synthase compared to the control group that all of these factors affect dilation and vascular proliferation (9). It seems that Botox is effective on recovery of scar and flap by increasing speed of tissue recovery and improve blood supply (11).

The concomitant effect of botulinum toxin and Plavix on skin flaps has not been investigated. This study is designed aimed to evaluate the concomitant effect of these two drugs and compare the effect of using each of these drugs alone. In the case of more effect of these drugs during concomitant use, application of random flaps will be easier and broader.

Methods:

Type of study: Research is carried out on laboratory rat of Sprague - Dawley of botulinum toxin Alay that can be purchased from Razi institute. Gender of all mice is male and age of all of them is the same, with no disease and weight of all of them is about 350 to 400 grams.

Forty prepared rats were randomly divided into 4 groups. The number of mice in each group was 10 mice and based on studying literature and formula of calculating sample was selected.

The study was interventional. All mice are kept based on recommendations of "Guide of the care and use of laboratory animals", 7th edition Published by the NRC 1997, ARENA/OLA Bvtvlvnyvm toxin A, Institutional Animal Care and Use Committee Guide Book, 2nd Edition 2002. Mice after surgery to stop eating wound of each other separately and in separate cages were kept and food and water were freely available to them. Time of transferring mice in laboratory and time of their staying in laboratory of animals until practice time was similar. After dividing rats randomly into four similar groups, all mice with drugs of ketamine, 10% with dose of 90 mg/Kg and Zaylazain 2% with a dose of 9 mg/Kg were intramuscularly unconscious and in the case of need of dose of drugs were repeated. Then hair of posterior part of mice shaved with an electric shaver and the place was disinfected with a solution of betadine and alcohol. Then Antibiotic prophylaxis with cefazolin

intramuscularly and with the amount of 60 mg/Kg was injected.

After insure of the depth of anesthesia with test of Pinch Flexion/Aal AithdraW W, surgery was started by observing methods of Asepsis. In the first group or the control group, random dorsal skin flap according to modified method of McFarlane and using a plastic model with dimensions of 3×10 cm that each one cm was specified to sutures based on the design distal and hip joint as specified point of flap was determined. Skin incision with a scalpel No. 15 was done and the flap to the substrate of Panisculus carnosus was raised. Any porfural vessel or cut axial and a transparent sterile sheet in the context of wound to prevent venesection of flap (graft Effect) can be attached from context. The skin flap is returned to its initial place and using nylon string 4 - zero cut was sewn. Then 0.5Cc normal saline was injected in the central part of one-third of the proximal of flap.

In the second group immediately after surgery as the method presented above, botulinum toxin with dose (international unit) 1.5 IU was injected as intradermal.

In the third group immediately after surgery clopidogrel powder that previously dissolved in a solution of sodium chloride orally using OGT (Orogastric Tube) and a dose of 25 mg/Kg is fed to animal. The drug at the same dose for 7 consecutive days repeated by OGT and also injected normal saline as a control with previous method.

In the fourth group, after surgery, botulinum toxin like the second group and Plavix composition like the third group with the same dose prescribed. All mice are kept under the same conditions and in separate containers.

At the end of the seventh day, all the animals first with analgesia method (gas CO₂) are destroyed and then photography with a digital camera can be done.

After the destruction of mice, a number of flat transparent glass that under it a calibrated caliper (to calibrate the computer) is attached (to uniformity of posterior surface of rat) was placed on rat and then photograph of all length of flap with a calibrated caliper with D300 Nikon digital camera and micro lens of 60 mm Nikon with a magnification of 1:10 and distance 80 cm is taken. Then images was transferred to the computer and the area of all flap

and area of necrosis level of each flap with software of Image J V.1.40 g (NIH, USA) after calibration is determined by square centimeter.

The histological evaluation of flap (necrotic and surviving part) by light microscopy was performed.

Samples of skin flap during steps of the clinical observation period which were separated from rat body were placed in 10% formalin immediately. Pathology samples after at least 24 hours that placed in 10% formalin were investigated apparently (macroscopic) by a pathologist and in terms of the apparent color - consistency - dimensions were evaluated, from each sample of skin at least 4 full width samples with width of 3-4 mm with full thickness were taken. Samples numbered in order from beginning to end flap. Finally, tissue samples from a half to 1 cm of the tissue.

Samples were numbered in order from beginning to end of flap. The first sample approximately with the distance of half to 1 cm from the beginning of tissue and other samples approximately with the distance of 2-3cm apart were sampled as identical and similar. The last sample of tissue has been from half to 1cm of end of tissue.

All samples were placed with discrete and identifiable numbers in special containers and prepared for the intake process with different percentages alcohols increasing in Tishoprocessor device and then molded with paraffin and each sample is placed on the block with the specified number. Blocked tissue samples prepared for cutting with microtome device that from the block (sample), at least 2 or more cutting with thickness of 2-3 micron prepared and placed on a slide and after steps of cutting prepared for stain on the slide that in this method, staining of the routine pathology Hematoksilin eosin E & H was performed.

After preparing slide for checking samples, first totally was studied and nearly all parts of cutting tissues evaluated and according to the existing table, the required parameters were observed and recorded. Different parameters due to intensity and presence or absence of them in different parts were also evaluated and registered.

Information obtained after the completion of the data collection form, by statistical software SPSS 11. 5 were analyzed. The distribution of quantitative data was checked in terms of normality.

In the analysis of results, statistical indicators of frequency, percentage, mean, median, mode, standard deviation and standard error was used. Comparing quantitative variables between two groups with statistical tests independent sample t-test (and, if necessary, Mann W Ahitney U test) and comparing quantitative variables between several groups using ANOVA (and, if necessary, Kruskal-Wallis H) is done. All fields of confident were calculated with 95%. Researchers at all stages of the project were committed to the principles of the Helsinki Convention and maintaining the mice was according to determined standards. Anesthesia

surgery and obliterate mice will be done with complete analgesia.

Results:

In this study, 40 surgeries were studied. The number of 10 mice in the control group and 10 rats in botulinum toxin group and 10 mice in the clopidogrel group and 10 mice in the clopidogrel group with botulinum toxin were compared.

Table 1. Comparison of epidemrmis necrosis in random skin flap in the blocks in studied groups

		Group				P-value
		Control	Botulinum toxin	Clopidogrel	Clopidogrel + Botulinum toxin	
The epidermal necrosis in the first block	50-75%	1 10.0%	0 0.0%	0 0.0%	0 0.0%	0.158
	25.50%	0 0.0%	0 0.0%	2 20.0%	0 0.0%	
	0-25%	9 90.0%	10 100.0%	8 80.0%	10 100.0%	
	75-100%	4 40.0%	0 0.0%	0 0.0%	0 0.0%	
The epidermal necrosis in the first block	50-75%	1 10.0%	0 0.0%	0 0.0%	0 0.0%	0.008
	25.50%	1 10.0%	1 10.0%	5 50.0%	2 20.0%	
	0.25%	4 40.0%	9 90.0%	5 50.0%	8 80.0%	
	75-100%	9 90.0%	4 40.0%	6 60.0%	3 30.0%	
The epidermal necrosis in the first block	50-75%	1 10.0%	1 10.0%	2 20.0%	0 0.0%	0.027
	25-50%	0 0.0%	2 20.0%	1 10.0%	6 60.0%	
	0-25%	0 0.0%	3 30.0%	1 10.0%	1 10.0%	
	75-100%	10 100.0%	9 90.0%	7 70.0%	7 70.0%	
The epidermal necrosis in the first block	50-75%	0 0.0%	1 10.0%	1 10.0%	2 20.0%	0.371
	25-50%	0 0.0%	0 0.0%	2 20.0%	1 10.0%	

Table 2. Comparison of necrosis in random skin flap in the blocks in studied groups

		Group				P-value
		Control	Botulinum toxin	Clopidogrel	Clopidogrel+ Botulinum toxin	
The dermis necrosis in the first block	75-100%	5 (83.3%)	0 (0.0%)	1 (16.7%)	0 (0.0%)	0.0001
	25-50%	1 (9.1%)	1 (9.1%)	9 (81.8%)	0 (0.0%)	
	0-25%	4 (17.4%)	9 (39.1%)	0 (0.0%)	10 (43.5%)	
The dermis necrosis in the first block	75-100%	3 (60.0%)	1 (20.0%)	1 (20.0%)	0 (0.0%)	0.002
	50-75%	1 (33.3%)	0 (0.0%)	2 (66.7%)	0 (0.0%)	
	25-50%	3 (25.0%)	1 (8.3%)	7 (58.3%)	1 (8.3%)	
The dermis necrosis in the first block	0-25%	3 (15.0%)	8 (40.0%)	0 (0.0%)	9 (45.0%)	0.029
	75-100%	10 (41.7%)	4 (16.7%)	7 (29.2%)	3 (12.5%)	
	50-75%	0 (0.0%)	1 (100.0%)	0 (0.0%)	0 (0.0%)	
The dermis necrosis in the first block	25-50%	0 (0.0%)	2 (20.0%)	3 (30.0%)	5 (50.0%)	0.5
	0-25%	0 (0.0%)	3 (60.0%)	0 (0.0%)	2 (40.0%)	
	75-100%	10 (28.6%)	9 (25.7%)	8 (22.9%)	8 (22.9%)	
The dermis necrosis in the first block	25-50%	0 (0.0%)	1 (25.0%)	1 (25.0%)	2 (50.0%)	0.5
	0-25%	0 (0.0%)	0 (0.0%)	1 (100.0%)	0 (0.0%)	

Table 3. Comparison of congestion in random skin flap in the blocks in studied groups

		Control				P-value
		Control	Botulinum toxin	Clopidogrel	Clopidogrel+ Botulinum toxin	
The congestin in the first block	.00	8 (28.6%)	7 (25.0%)	8 (28.6%)	5 (17.9%)	0.37
	1.00	1 (10.0%)	2 (20.0%)	2 (20.0%)	5 (50.0%)	
	2.00	1 (50.0%)	1 (50.0%)	0 (0.0%)	0 (0.0%)	
The congestin in the first block	.00	6 (27.3%)	4 (18.2%)	6 (27.3%)	6 (27.3%)	0.18
	1.00	1 (12.5%)	1 (12.5%)	2 (25.0%)	4 (50.0%)	
	2.00	3 (30.0%)	5 (50.0%)	2 (20.0%)	0 (0.0%)	
The congestin in the first block	.00	1 (14.3%)	2 (28.6%)	2 (28.6%)	2 (28.6%)	0.39
	1.00	3 (50.0%)	0 (0.0%)	0 (0.0%)	3 (50.0%)	
	2.00	5 (20.0%)	8 (32.0%)	7 (28.0%)	5 (20.0%)	
The congestin in the first block	3.00	1 (50.0%)	0 (0.0%)	1 (50.0%)	0 (0.0%)	0.70
	.00	1 (50.0%)	0 (0.0%)	0 (0.0%)	1 (50.0%)	
	1.00	2 (28.6%)	0 (0.0%)	1 (14.3%)	4 (57.1%)	
The congestin in the first block	2.00	5 (17.2%)	10 (34.5%)	9 (31.0%)	5 (17.2%)	0.70
	3.00	2 (100.0%)	0 (0.0%)	0 (0.0%)	0 (0.0%)	

The average of necrosis in the control group 21 ± 2 in botulinum toxin A group 9.3 ± 0.8 in clopidogrel group 14 ± 1.7 and in clopidogrel + botulinum toxin A was 12.6 ± 1.5 percent. The difference was statistically significant between groups.

The control group had significantly more necrosis to all groups ($P < 0.0001$).

The necrosis of botulinum toxin A group was less than control group ($P < 0.0001$), less than group P ($P < 0.0001$) and less than clopidogrel + botulinum toxin A ($P = 0.003$), respectively.

Average of necrosis of clopidogrel group was less than the control group ($P < 0.0001$) and more than botulinum toxin A ($P < 0.0001$) and didn't differ with clopidogrel + botulinum toxin A ($P = 0.324$).

The average of necrosis in clopidogrel group + botulinum toxin A was less than control group ($P < 0.0001$) and more than botulinum toxin A ($P < 0.0001$) and didn't differ with clopidogrel group ($P = 0.32$). Figure 1 shows the average of necrosis.

Compare pathology slides are shown in Tables 1-4. Pathological slides image is shown in Figure 1.

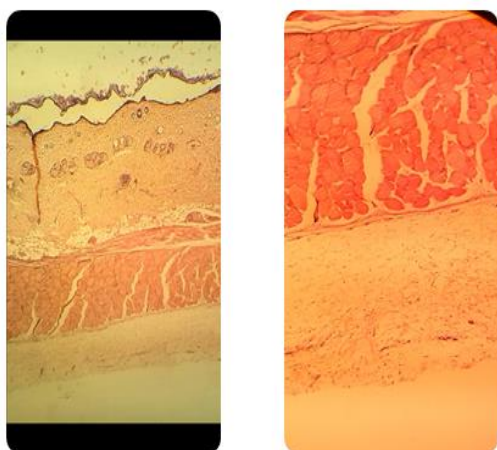


Figure 1. Angiogenesis in the Botox group (left) compared to control group (right).

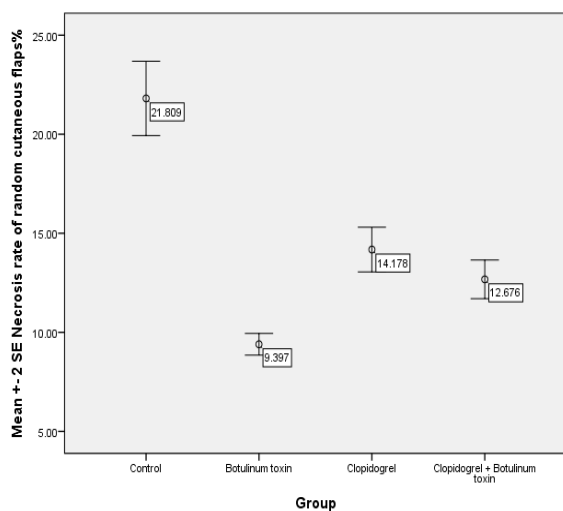


Figure 1. Graph of the mean of necrosis in studied groups

Conclusion:

The findings of our study showed that injection of botulinum toxin compared to the control group and compared to clopidogrel group and clopidogrel combined with botulinum toxin A show greater effect on the survival of flap and reduce distal necrosis.

This is the first study that compares the botulinum toxin A compared to the control group and compared to clopidogrel group and clopidogrel combined with botulinum toxin A. Previous studies had shown the effects of botulinum toxin A alone. In line with this study Yidrim and colleagues

demonstrated that the use of botulinum toxin A, two weeks after lifting the flap causes to reduce necrosis area (10).

Ersoy and colleagues a study evaluated the effect of clopidogrel on flap survival (6).

Clopidogrel in animal models reduces the incidence of arterial and venous and in heart disease with the treatment of PCI is used (12,13). But effect of botulinum toxin A was better than the effect of clopidogrel and the combination of these two in flap survival. Mechanism of these two drugs is different.

The basis of the mechanism of botulinum toxin A is block of releasing acetylcholine from the neuron's presynaptic. Morris noted that botulinum toxin A can inhibit the secretion of NEPY of perivascular nerves as botulinum toxin A blocks the release of Ach from presynaptic (14). Kim showed the effects of anti-sympathetic of botulinum toxin A (9) and Arnold reported anti-inflammatory effects of botulinum toxin A (15,16). However, based on the results of our study we did not see anti-inflammatory effect from botulinum toxin A and the congestion in all groups was equal. The other mechanisms involved in relation to botulinum toxin A can refer to Clemens study.

Based on the observations of Clemens, botulinum toxin type A was successful in the prevention of thrombosis in this animal model. In that study, it was suggested that botulinum toxin type A has the ability to reduce vasospasm and thrombosis and may have applications to improve flap survival in some patients (17).

In our observations, the necrosis of Clopidogrel group was lower than control group. This drug after an hour reaches to the appropriate bioavailability in the plasma. The mechanism of clopidogrel effect on flap survival can be considered in preventing platelet aggregation. Effective drug concentration of clopidogrel in animal was in the oral absorption according to previous studies.

Blood circulation in the skin layers is the most important factor in the survival of random skin flap. Blood circulation due to hormonal and neurological mechanisms is controlled (18). It seems both of the used materials in this study have caused increase of blood flow.

In connection with the effect of what it was justified, additional and more detailed testing is

required, but regardless of the errors caused by experimental tests could be considered that botulinum toxin type A with a mechanism of other than angiogenesis reduces necrosis because in view of pathological angiogenesis in other than block a, proximal in other groups is equal. If the necrotic of epidermis and dermis in block b and c in this study was more important due to more distal. Necrosis of the dermis and epidermis based on observations and statistical analysis in this study in the group of botulinum toxin A significantly is lower in the block b and c. Or according to the above studies, mechanism of this observation can be justified in sampatolic of botulinum toxin A and not applications of angiogenesis or congestion.

Stone reports in 2012 supports this finding. Stone with topical use of botulinum toxin A observed arteries dilation with 69% efficiency increase of blood flow, without change systemic arterial pressure in rat (19). In addition, the study of Dennis in 2013 by method of immunofluorescence vascular, tissue, cellular and molecular showed that Botox injection causes flap survival by improving blood flow and oxygen delivery (20). However, to confirm this finding suggests that future studies done on adrenergic blockers or antagonists sympathetic as injectable drugs in random skin flap.

Recommended that the amount of noradrenaline in the region of flap measured or similar sampatolic used.

References:

1. Livaoglu M, Kerimoglu S, Sonmez B, Livaoglu A, Karacal N. The effect of Hirudoid on random skin-flap survival in rats. *J Plast Reconstr Aesthet Surg.* 2010;63(6):1047-1051.
2. Gulmez SE, Serel S, Uluc A, Can Z, Ergun H. Dipyron increases the blood flow of arterial dorsal skin flaps. *Aesthetic Plast Surg.* 2008;32(5):766-770.
3. Huemer GM, Wechselberger G, Otto-Schoeller A, Gurunluoglu R, Piza-Katzer H, Schoeller T. Improved dorsal random-pattern skin flap survival in rats With a topically applied combination of nonivamide and nicoboxil. *Plast Reconstr Surg.* 2003;111(3):1207-1211.
4. Hart K, Baur D, Hodam J, Lesoon-Wood L, Parham M, Keith K, Vazquez R, et al. Short- and long-term effects of sildenafil on skin flap survival in rats. *Laryngoscope.* 2006;116(4):522-528.
5. Akan M, Cakir B, Misirlioglu A, Yildirim S, Taylan G, Akoz T. Effects of clopidogrel and high dose aspirin on survival of skin flaps in rats. *Scand J Plast Reconstr Surg Hand Surg.* 2005;39(1):7-10.
6. Ersoy A, Sevin K, Sevin A, Serel S. Effects of clopidogrel on survival of rat skin flaps. *J Plast Reconstr Aesthet Surg.* 2007;60(8):861-863.
7. Shalom A, Friedman T, Westreich M. Effect of aspirin and heparin on random skin flap survival in rats. *Dermatol Surg.* 2008;34(6):785-790.
8. Fathi M, Fathi H, Mazlumi M, Khalilzadeh O, Amanpour S, Meysamie A, et al. Preventive effect of botulinum toxin A in microanastomotic thrombosis: a rabbit model. *J Plast Reconstr Aesthet Surg.* 2010;63(10):720-724.
9. Kim TK, h EJ, Chung JY, Park JW, Cho BC, Chung HY. The effects of botulinum toxin A on the survival of a random cutaneous flap. *J Plast Reconstr Aesthet Surg.* 2009;62(7):906-913.
10. Yildirim AM, Okur I, Orter Z, Uysal A. Nonsurgical delay of dorsal rat cutaneous flap using botulinum toxin type A. *Plast Reconstr Surg.* 2008;122(1):53e-54e.
11. Duan C, Xu G, Zhou J, Wei G, Li S. Effect of botulinum toxin type A on excessive expansion of myocutaneous flap. *Zhongguo Xiu Fu Chong Jian Wai Ke Za Zhi.* 2011;25(9):1063-1066.
12. Roden DM, Shuldiner AR. Responding to the clopidogrel Warning by the US food and drug administration: real life is complicated. *Circulation.* 2010;122(5):445-448.

13. Gurbel PA, Tantry US. Combination antithrombotic therapies. *Circulation*. 2010;121(4):569-583.
14. Morris JL, Jobling P, Gibbins IL. Botulinum neurotoxin A attenuates release of norepinephrine but not NPY from vasoconstrictor neurons. *Am J Physiol Heart Circ Physiol*. 2002;283(6): 2627-2635.
15. Zhang F, Waller W, LineaWeaver WC. GroWth factors and flap survival. *Microsurgery*. 2004;24(3):162-167.
16. Arnold PB, Fang T, Songcharoen SJ, Ziakas G, Zhang F. Inflammatory response and survival of pedicled abdominal flaps in a rat model after perivascular application of botulinum toxin type a. *Plastic Reconstr Surg*. 2014;133(4):491e-498e.
17. Clemens MW, Higgins JP, Wilgis EF. Prevention of anastomotic thrombosis by botulinum toxin a in an animal model. *Plast Reconstr Surg*. 2009;123(1):64-70.
18. Daniel RK, Kerrigan CL. Principles and physiology of skin flap surgery. Philadelphia: WB Saunders; 1990. p. 275-328.
19. Stone AV, Koman LA, Callahan MF, Eckman DM, Smith BP, Plate JF, et al. The effect of botulinum neurotoxin-A on blood flow in rats: a potential mechanism for treatment of Raynaud phenomenon. *J Hand Surg Am*. 2012;37(4):795-802.
20. SchWeizer DF, SchWeizer R, Zhang S, Kamat P, Contaldo C, et al. Botulinum toxin A and B raise blood flow and increase survival of critically ischemic skin flaps. *J Surg Res*. 2013;184(2):1205-1213.

مقایسه اثر سم بوتولینیوم و کلوییدوگرل و تجویز همزمان آنها در بقاء فلپ پوستی راندم در موش رت

دکتر فردوس مزنبی^۱ دکتر قاسمعلی خراسانی^۲ دکتر سیدابوذر حسینی^۳ دکتر کوروش قنبرزاده^۴ دکتر مسعود اینالو^۵ دکتر بتول قربانی یکتا^۶
^۱ استادیار گروه جراحی، دانشگاه علوم پزشکی هرمزگان^۲ دانشیار گروه جراحی، دانشگاه علوم پزشکی تهران^۳ متخصص پاتولوژی، دانشگاه علوم پزشکی ایران^۴ استادیار گروه جراحی، دانشگاه علوم پزشکی تهران^۵ استاد گروه داروسازی، دانشگاه علوم پزشکی تهران^۶ استادیار گروه داخلی، مرکز تحقیقات علوم اعصاب، دانشگاه آزاد، واحد علوم پزشکی تهران

مجله پزشکی هرمزگان سال نوزدهم شماره پنجم آذر و دی ۹۴ صفحات ۴۲۳-۴۱۵

چکیده

مقدمه: در این مطالعه، اثر سم بوتولینیوم A و کلوییدوگرل و تجویز همزمان آنها در بقاء فلپ پوستی راندم در موش رت مورد بررسی قرار گرفت.

روش کار: ابتدا در تمام رت ها فلپ های $3 \times 1.0 \text{ cm}$ ایجاد شد. گروه اول گروه کنترل بود. در گروه دوم بلافاصله بعد از انجام عمل جراحی سم بوتولینیوم با دوز $1/5 \text{ IU}$ (international unit) به صورت داخل جلدی تزریق می شد. در گروه سوم، بلافاصله بعد از انجام عمل جراحی، پودر کلوییدوگرل که قبلاً در محلول کلرور سدیم حل شده به صورت خوراکی با استفاده از (Orogastric Tube) OGT و با دوز 25 mg/Kg به حیوان خوراند می شد. در گروه چهارم نیز بعد از انجام عمل جراحی، سم بوتولینیوم مانند گروه دوم و ترکیب پلاویکس همانند گروه سوم با همان دوز تجویز می شدند. پس از ۷ روز سطوح برش فلپ تحت اندازه گیری و محاسبات مورفولوژی و پاتولوژی قرار گرفت.

نتایج: میانگین نکروز در گروه کنترل 21 ± 2 در گروه سم بوتولونیوم $9/3 \pm 0/8A$ در گروه کلوییدوگرل $14 \pm 1/7$ و در گروه کلوییدوگرل + سم بوتولونیوم $12/6 \pm 1/5A$ درصد بود. اختلاف بین گروه ها از نظر آماری معنی دار بود ($P < 0/001$).

نتیجه گیری: یافته مطالعه ما نشان داد که تزریق سم بوتولونیوم A نسبت به گروه کنترل و نسبت به گروه کلوییدوگرل و ترکیب کلوییدوگرل با سم بوتولونیوم A اثر بیشتری را در بقای فلپ و کاهش نکروز دیستال نشان می دهد.

کلیدواژه ها: فلپ، نکروز، سموم بوتولینیوم، کلوییدوگرل

نویسنده مسئول:

دکتر قاسمعلی خراسانی
 گروه جراحی، مجتمع بیمارستانی امام
 خمینی، دانشگاه علوم پزشکی تهران
 تهران- ایران

تلفن: +۹۸ ۹۱۲ ۷۲۱۳۹۴۸

پست الکترونیکی:

GAKhorasani@yahoo.com

دریافت مقاله: ۹۳/۵/۱۵ اصلاح نهایی: ۹۳/۶/۲۰ پذیرش مقاله: ۹۳/۶/۲۵