

Case Report

Ovarian dermoid cyst and neuromuscular manifestation

Maryam Esmaeili¹, Shirin Shahbazi^{2*}, Khatereh Seylani³, Nasrin Nazari⁴

¹ School of Nursing and Midwifery, Nursing and Midwifery Care Research Center, Tehran University of Medical Sciences, Tehran, Iran

² Department of Reproductive Health, School of Nursing and Midwifery, Tehran University of Medical Sciences, Tehran, Iran

³ Department of Critical Care, School of Nursing and Midwifery, Tehran University of Medical Sciences, Tehran, Iran

⁴ School of Nursing and Midwifery, Islamic Azad University, Karaj Branch, Karaj, Iran

ARTICLE INFO

Received 8 August 2015
Revised 12 November 2015
Accepted 4 December 2015
Published 29 December 2015

Available online at:
<http://npt.tums.ac.ir>

Key words:
dermoid cyst,
ovary,
neuromuscular

ABSTRACT

Background & Aim: To reported a case of ovarian dermoid cyst with abnormal clinical manifestation.

Case Report: We present a 53-year-old woman with loss of muscle strength in lower extremities (in both legs) and gait abnormalities due to ovarian dermoid cyst. The following severe disability and dependence on wheelchair, the patient attended hospital in March 2015 and underwent surgery. Currently, the patient has no particular problem, and examination of the legs shows normal reflexes and muscle strength, and she does her daily chores without motor dependence.

Conclusion: The presence of non-specific symptoms requires careful follow-up and patient holistic assessment.

Introduction

Germ cell tumors constitute 15-20% of ovarian tumors, and the majority of them are mature cystic teratomas (1). Teratomas are divided into four categories: mature (cystic or solid, benign), Immature (malignant), malignant due to a component of another somatic malignant neoplasm, and mono dermal or highly specialized (2, 3). Most teratomas are cystic and composed of mature differentiated; they are better known as dermoid cyst. The mature cystic teratomas account for more than 95% of all ovarian teratomas and are almost invariably benign. Dermoid cyst is the most common ovarian tumor in women in the second and third decade of life (4). Most women with dermoid cysts are asymptomatic,

if present, symptoms depend on the size of the mass, torsion is not common, rupture of dermoid cysts with spillage of sebaceous material into the abdominal cavity can occur but is uncommon (5, 6). Shock and hemorrhage are the immediate sequelae of rupture; a marked granulomatous reaction (chemical peritonitis) may subsequently develop and lead to the formation of dense adhesions (1, 7). In this study, we reported a case of ovarian dermoid cyst with abnormal clinical manifestation.

Case Report

A 53-year-old woman with loss of muscle strength in lower extremities (in both legs) and gait abnormalities presented to a neurologist in September 2014. The patient had not report a history of any diseases or use of any particular medication. Physical examination revealed muscle weakness and hypo-reflex in her legs. Electromyography (EMG), Brain Magnetic Resonance Imaging (BMRI) and

* Corresponding Author: Shirin Shahbazi, Postal Address: Department of Reproductive Health, School of Nursing and Midwifery, Tehran University of Medical Sciences, Tehran, Iran.
Email: shahbazishirin@yahoo.com

routine laboratory tests produced normal results. Magnetic resonance imaging (MRI) indicated lumbar bulging in L5-S1 and L4-L5 discs, for which, 20 sessions of physiotherapy of the back and legs were advised. However, physiotherapy did not abate clinical symptoms of the patient, and her impaired movement worsened with progressive hypo-reflex. In her next visit to the neurologist, Guillain-Barre syndrome was suggested and tests were repeated, which were all normal again. Following progressive gait abnormality in her legs and dependence on walking frame, she visited another neurologist, where physical examinations revealed symptoms of neuromuscular disorder, and repeat EMG and assessment of serum copper, lead, and zinc levels and thoracic MRI were requested. In EMG/nerve conduction study (NCS), neurological changes and muscular Serratus Anterior (SA) were observed in the legs. The second EMG/NCS suggested early motor neuron disease, and thus, two Riluzole tablets per day were administered. In thoracic MRI, the radiologist accidentally reported a large septated solid-cystic mass lesion of 7 cm × 7 cm diameter in the pelvic cavity, and therefore, ovarian tumor was considered likely. After consultation with the neurologist and referral for surgery, tumor markers were controlled, and carcinoembryonic antigen = 7 ng/mL and cancer antigen 19 = 65 U/ml were reported. The surgeon requested contrasted abdominal and pelvic computed tomography, and a dermoid cyst of 70 mm × 78 mm dimensions in the right ovary and upper uterus was reported (Figures 1 and 2).

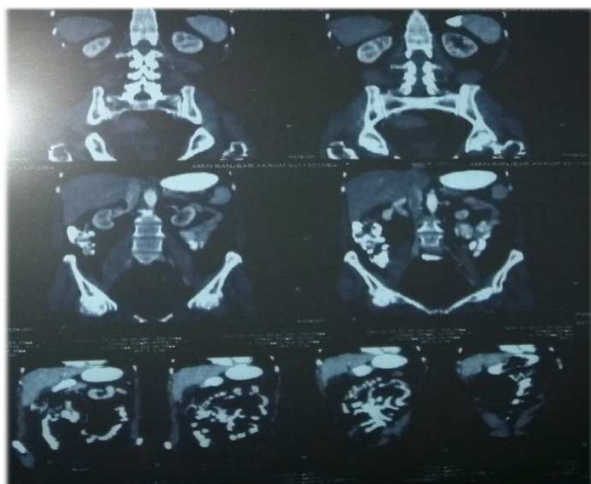


Figure 1. Abdomino pelvic computed tomography

The following severe disability and dependence on wheelchair, the patient attended hospital in March 2015 and underwent surgery. Pathology also reported a benign dermoid cyst. In April 2015, about 25 days after surgery, gait abnormalities abated and the patient was gradually able to walk. Currently, the patient has no particular problem, and examination of the legs shows normal reflexes and muscle strength, and she does her daily chores without motor dependence.

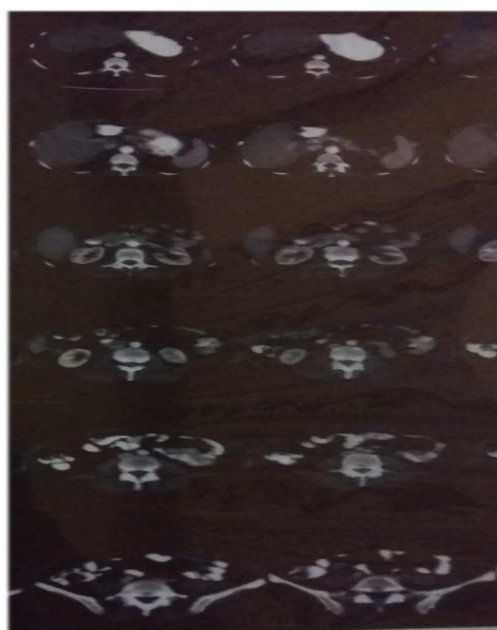


Figure 2. Abdomino pelvic computed tomography

Discussion

The ovarian teratomas may be mature or immature and include histological diversity in ectoderm, mesoderm, and endoderm embryonic layers (8), which cause different signs and symptoms depending on their severity. The asymptomatic post-menopausal ovarian dermoid cyst is very rare. In this study, a post-menopausal patient with dermoid cyst and amyotrophic lateral syndrome (ALS)-like symptoms was reported.

Very few studies have cited numerous symptoms of ovarian teratomas and dermoid cyst (9), and mainly referred to specific and common symptoms, which include infection, rupture, shock, bleeding, and torsion (1). Ovarian torsion accounts for 16% of complications related to ovarian teratomas, and the

most common risk factors for ovarian torsion is the present of dermoid cyst (10).

Some articles have cited a headache and behavioral changes, which were not observed in this patient. Some articles have argued that symptoms of ovarian teratomas including dermoid cyst overlap with other diseases. However, no case study has ever reported symptoms such as impaired movement and ALS, and this requires further and holistic examination of patients to accurately diagnose the disease (9). The presence of non-specific symptoms requires careful follow-up and holistic assessment of many laboratory results to help the patient. Our review of literature suggests that neuromuscular manifestations such ALS in ovarian dermoid cyst is an exactly uncommon event and it is very rare in post-menopause. However, based on our case, neuromuscular manifestations should be considered in the differential diagnosis.

Acknowledgments

The first author would like to thank Dr. Iraj Fazel and all nurses that work in Iranmehr Hospital.

Conflict of interest

The authors declare no conflict of interest.

References

1. Hasanzadeh M, Tabare SH, Mirzaean S. Ovarian dermoid cyst. *Professional Med J* 2010; 17(3): 512-5.
2. Pectasides D, Pectasides E, Kassanos D. Germ cell tumors of the ovary. *Cancer Treat Rev* 2008; 34(5): 427-41.
3. Smith HO, Berwick M, Verschraegen CF, Wiggins C, Lansing L, Muller CY, et al. Incidence and survival rates for female malignant germ cell tumors. *Obstet Gynecol* 2006; 107(5): 1075-85.
4. Shaco-Levy R, Bean SM, Bentley RC, Robboy SJ. Natural history of biologically malignant struma ovarii: analysis of 27 cases with extraovarian spread. *Int J Gynecol Pathol* 2010; 29(3): 212-27.
5. Raman A, Sinha G, Sinha A, Pratap S. Subtle presentation of bilateral ovarian dermoid cysts with unilateral torsion: a case report. *J Clin Gynecol Obstet* 2015; 4(2): 232-4.
6. Ayhan A, Bukulmez O, Genc C, Karamursel BS, Ayhan A. Mature cystic teratomas of the ovary: case series from one institution over 34 years. *Eur J Obstet Gynecol Reprod Biol* 2000; 88(2): 153-7.
7. Duigenan S, Oliva E, Lee SI. Ovarian torsion: diagnostic features on CT and MRI with pathologic correlation. *AJR Am J Roentgenol* 2012; 198(2): W122-W131.
8. Bhasin SK, Malik SM, Sharma G, Gupta SK. Ovarian dermoid presenting as acute intestinal obstruction: a rare case report and review of literature. *Int Surg J* 2015; 2(2): 283-5.
9. Murdoch W, Sadoski J, Rosin FC. Multisystem manifestations of benign ovarian teratomas. *J Am Board Fam Med* 2014; 27(3): 421-3.
10. Trehan A, Trehan AK. Laparoscopic management of a dermoid cyst containing a tooth-bearing mandible-like structure and possible chronic adnexal torsion. *J Obstet Gynaecol* 2014; 34(7): 656-7.